

Received: September 17, 2017

Accepted: October 21, 2017

Published: October 23, 2017

*CORRESPONDING AUTHOR:

Devanshi Dharaiya, Department of
Neurology, Henry Ford Hospital, 2799 W.
Grand Blvd., Detroit, MI 48202, USA,
Email: ddharai1@hfhs.org

KEYWORDS

Recurrent thromboembolism; Carotid
endarterectomy; Carotid artery stenting;
Carotid stent removal

CITATION

Devanshi Dharaiya, Sarah Madani,
Sumul Modi, Daniel Miller, and Judith
C. Lin² *J Med Surg.* (2017). Recurrent
Thromboembolic Complications After
Carotid Artery Revascularization. *SciTz
Neurosurg Spine.* 2017. 2(1): 1005.

Case Report

Recurrent Thromboembolic Complications After Carotid Artery Revascularization

Devanshi Dharaiya^{1*}, Sarah Madani¹, Sumul Modi¹,
Daniel Miller¹, and Judith C. Lin²

¹Department of Neurology, Henry Ford Hospital, USA

²Division of Vascular Surgery, Henry Ford Hospital, USA

Abstract

Symptomatic severe carotid artery stenosis is treated with either carotid endarterectomy (CEA) or carotid artery stenting (CAS). Either of these procedures may be complicated by thrombosis of the treated segment of the extracranial carotid artery. We present a patient who underwent CAS which was complicated by in-stent thrombosis thirteen years later. He underwent CEA for acute left hemispheric stroke which was again complicated by deposition of thrombi within the bovine pericardial patch causing amaurosis fugax. Dual anti-platelet treatment with aspirin and clopidogrel resulted in imaging resolution and no recurrence of symptoms.

Introduction

North American Symptomatic Carotid Endarterectomy Trial (NASCET), the European Carotid Surgery Trial (ECST), and the Asymptomatic Carotid Atherosclerosis Study (ACAS), have all established carotid endarterectomy (CEA) as the gold standard treatment for patients with symptomatic severe stenosis ($\geq 70\%$) (Class I-level of evidence B) [1]. Carotid artery stenting (CAS) is sometimes preferred in younger patients given the cosmetic advantages of being less invasive without a cervical incision. Following carotid endarterectomy, early postoperative thrombosis or late restenosis occurs in up to 20% of vessels. Both complications may be related to platelet mechanisms [2]. Bovine pericardial patch anastomosis combines the advantages of autologous and synthetic properties, representing a suitable option when performing CEA [3]. It is highly likely that platelet mechanisms contribute to the carotid restenosis. In animal models, mechanical injury to the arterial wall leads to platelet adherence and gross platelet-fibrin thrombus on the denuded vessel [4]. Lesions developing within the first 24 months have been composed primarily of exuberant myointimal hyperplasia

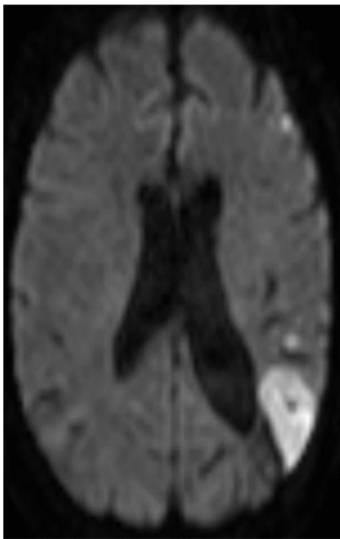


Figure 1: MRI reveals acute left parietal infarct

with scarce lipid deposits, whereas later lesions are usually composed of atheromas [5].

Case Presentation

The patient is a 59 year-old male with a history of uncontrolled diabetes, hyperlipidemia and hypertension. He had a remote history of traumatic left internal carotid artery dissection in 1996, and presented with a left parietal stroke that was treated with CAS in 2003. Subsequently, he presented in 2016 with partially occluding in-stent

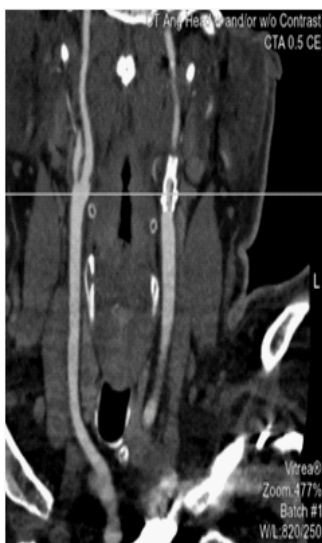

Figure 2: CTA shows acute left internal carotid stenosis. Stent visualized in-situ.

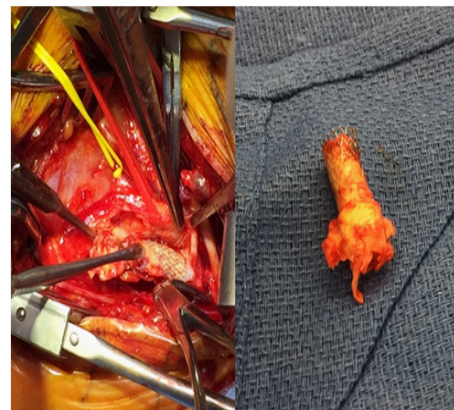

Figure 3: Carotid endarterectomy performed for stent removal. Resected stent with in-stent thrombosis.

thrombus and acute left hemispheric stroke, which was treated with intravenous alteplase. Etiology of the stroke was partially occluding in stent thrombosis of the left internal carotid artery. He underwent CEA under general anesthesia and the carotid stent was removed en bloc along with the underlying atheromatous disease. Pathologic examination was not requested. The carotid arteriotomy was closed using Vascu-Guard bovine pericardial patch angioplasty and 6-0 running polypropylene sutures. The Patient was discharged on aspirin 325 mg.

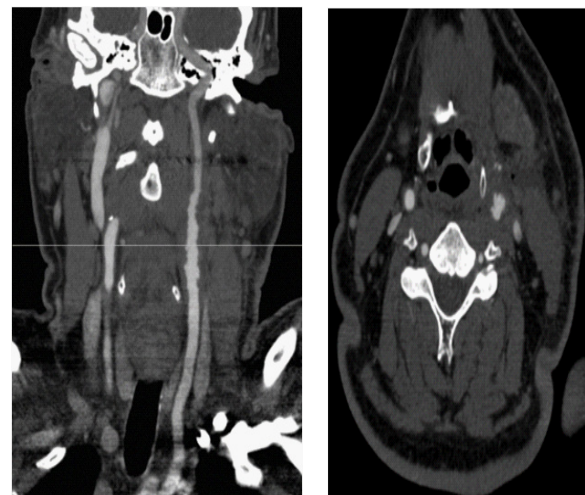


Figure 4: Repeat CTA imaging 2 weeks post-operatively shows significant irregularity on the intimal surface of the bovine pericardial patch.

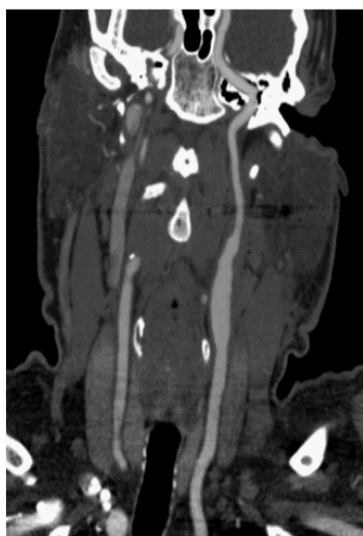

Figure 5: Resolution of intimal surface irregularity after dual antiplatelet therapy for 6 months.

Two weeks later he developed amaurosis fugax in the ipsilateral eye. Computed tomography angiography (CTA) revealed significant irregularity on the intimal surface of the patch. This was considered secondary to deposition of numerous thrombi on the vessel lining. Amaurosis fugax was considered to be secondary to distal embolization of these thrombi. He was started on treatment with dual antiplatelet drugs – aspirin and clopidogrel. Follow up CTA 6 weeks later revealed significant resolution of the vessel wall irregularity. He was seen in clinic 7 months later with exam revealed mild neurological deficits consisting of mild right hemiparesis and expressive aphasia without any further recurrences. He has been maintained on Aspirin and Clopidogrel along with aggressive medical management and has not had any recurrence of symptoms (Figure 1-5).

Discussion

We present a case of carotid stent removal and CEA using a bovine pericardial patch that was complicated by aggregation of thrombi on the intimal surface and subsequent episode of amaurosis fugax. Well-known complications after CAS are brain emboli and in-stent restenosis (ISR). Clinical ISR complication rates vary widely in the literature with stroke rates between 0% and 25% and death rates from 0% to 11%. ISR frequently

happens in the first year and can have significant impact on the long-term risk of stroke and death [6].

Aspirin therapy has been shown to reduce the relative risk of thromboembolic stroke by 20% to 25% [7]. Aspirin inhibits only one of the several pathways of platelet activation. Failure to prevent thromboembolization in carotid surgery suggests that platelet activation through an aspirin-insensitive pathway may be more important in promoting arterial thromboembolization in this setting [8]. Although aspirin inhibits the generation of thromboxane A₂ by blocking COX-1, clopidogrel exerts its antiplatelet effect by a different mechanism, blocking the platelet P2Y₁₂ ADP receptor [9].

Efficacy of clopidogrel over aspirin have already been established for cardiovascular events in CAPRIE trial with 8.7% reduction in the relative risk for the composite endpoint of ischemic events, no difference was seen in the subset of patients with previous ischemic stroke (RR, 7.3%; 95% CI, 5.7–18.7) [10]. Restenosis after CAS likely results from vessel wall injury and subsequent neointimal hyperplasia which occurs within 24 months of the postoperative period or de novo neoatherosclerosis thereafter [11]. Neointimal hyperplasia is a stable condition, usually peaking 3 months after surgery, and followed by a regression. It develops from the continuous interaction between the stent and the vessel which causes physical irritation, endothelial dysfunction, and chronic inflammation [12].

The rate of significant restenosis; defined as 60% or more using duplex sonography; after carotid bovine pericardial patch angioplasty was reported in one study to be 5% after one year, and all those patients were asymptomatic [13]. In our case, we believe that aggregation of numerous small platelet-fibrin thrombi on the bovine pericardial patch surface is the likely mechanism of pathogenesis. Authors also propose dual antiplatelet drugs as an effective treatment modality.

References

1. Ricotta JJ, Aburahma A, Ascher E, Eskandari M, et al. Updated Society for Vascular Surgery guidelines for management of extracranial carotid disease: executive summary. *J Vasc Surg.* 2011; 54: 832-836.
2. Stratton JR, Zierler RE, Kazmers A. Platelet deposition at carotid endarterectomy sties I humans. *Stroke.* 1987; 18: 722-727.
3. Papakostas JC, Avgos S, Arnaoutoglou E, Nassis C Peroulis. Use of the vascu-guard bovine pericardium patch for arteriotomy closure in carotid endarterectomy. Early and long-term results. *Ann Vasc Surg.* 2014; 28: 1213-1218.
4. Ross R. George Lyman Duff Memorial Lecture. Atherosclerosis: a problem of the biology of arterial wall cells and their interactions with blood components. *Arteriosclerosis.* 1981; 1: 293-311.
5. Cossman D, Callow AD, Stein A, Matsumoto G. Early restenosis after carotid endarterectomy. *Arch Surg.* 1978; 113: 275- 278.
6. Wasser K, Schnaudigel S, Wohlfahrt J, Psychogios MN, et al. Clinical impact and predictors of carotid artery in-stent restenosis. *J Neurol.* 2012; 259: 1896-1902.
7. Antithrombotic Trialists; Collaboration. Collaborative meta-analysis of randomized trials of antiplatelet therapy for prevention of death, myocardial infarction, and stroke in high risk patients. *BMJ.* 2002; 324: 71-86.
8. Payne DA, Jones CI, Hayes PD, Thompson MM, et al. Beneficial effects of clopidogrel combined with aspirin in reducing cerebral emboli in patients undergoing carotid endarterectomy. *Circulation.* 2004; 109: 1476-1481.
9. Warner TD, Nylander S, Whatling C. Anti-platelet therapy: cyclo-oxygenase inhibition and the use of aspirin with particular regard to dual anti-platelet therapy. *Br J Clin Pharmacol.* 2011; 72: 619-633.
10. CAPRIE Steering Committee. A randomized, blinded, trial of clopidogrel versus aspirin in patients at risk of ischemic events (CAPRIE). *Lancet.* 1996; 348: 1329-1339.
11. Lal BK, Kaperonis EA, Cuadra S, Kapadia I, et al. Patterns of in-stent restenosis after carotid artery stenting: Classification and implications for long-term outcome. *J Vasc Surg.* 2007; 46: 833-840.
12. Zubilewicz T, Wronski J, Bourriez A, Terlecki P, et al. Injury in vascular surgery—the intimal hyperplastic response. *Med Sci Monit.* 2001; 7: 316-324.
13. Marien BJ, Raffetto JD, Seidman CS, LaMorte WW, et al. Bovine Pericardium vs Dacron for Patch Angioplasty after Carotid Endarterectomy. *Arch Surg.* 2002; 137: 785-788.